

## CASE REPORT

# Congenital vaginal obstruction in a newborn

Nader Mutwakel Osman (1), Abdelbagi Mustafa Hamza (2), Hiba Asim Mustafa Elamin (2)

(1) Department Paediatrics and Child Health, Omdurman Islamic University, Sudan

(2) Soba university Hospital, Khartoum, Sudan

### ABSTRACT

A transverse vaginal septum is a horizontal wall of tissue that has formed during embryologic development and essentially creates a blockage of the vagina. It can occur at different levels of the vagina. We report a neonate who was diagnosed antenatally with an enlarged lower abdominal mass suggestive of an enlarged urinary bladder with hydronephrosis and hydroureter. Shortly after birth, she developed urinary retention and neonatal sepsis. Following multiple postnatal investigations, she was found to have a vaginal septum with hydrometrocolpos.

### KEYWORDS

Vaginal septum; Newborn; Hydrometrocolpos; Hydronephrosis.

### INTRODUCTION

Hydrocolpos is the distension of the vagina caused by the accumulation of fluid due to congenital vaginal obstruction. It is often caused by imperforate hymen or less commonly a transverse vaginal septum. The fluid itself consists of cervical and endometrial mucus, and in severe cases, the fluid might accumulate up to the uterus, and the term hydrometrocolpos is used. It has an estimated

incidence of ~0.006% per year in full-term newborns [1]. Several anomalies were associated with this condition, such as imperforate anus or persistent urogenital sinus. It was also found to be part of a genetic syndrome, such as Bardet–Biedl, McKusick–Kaufman, and Pallister–Hall [1].

Congenital vaginal obstruction usually presents itself after puberty, and presentation in the first year of life is uncommon. Due to lack of awareness, diagnosis may be missed in infants leading to serious consequences [2]. The clinical features in the newborn period are dominated by the lower abdominal mass with compression of adjacent structures, commonly the urinary bladder. Urinary retention is rare in children, especially in newborns, and its association with abdominal distention in a female neonate should raise the suspicion of hydrocolpos [1]. Physical examination may be completely normal in cases of vaginal septum and a complete pelvic examination with vaginoscopy may be necessary [3]. Complications like hydronephrosis and gastrointestinal obstruction secondary to mass effect make it imperative that these infants should be evaluated and treated soon after birth.

### CASE REPORT

A female newborn was the product of spontaneous vaginal delivery at Soba University Hospital at 37

### Correspondence to:

Nader Mutwakel Osman  
Department of Paediatrics and Child Health,  
Omdurman Islamic University, Omdurman,  
Sudan

Email: nadermosman@gmail.com

Received: 02 December 2018 | Accepted: 21 November 2019

### How to cite this article:

Osman NM, Hamza AM, Elamin HAM.  
Congenital vaginal obstruction in a newborn.  
Sudan J Paediatr. 2019;19(2):145–148.  
<https://doi.org/10.24911/SJP.106-1543747330>

weeks gestational age to a multiparous mother aged 40 years. The baby cried immediately with an Apgar score of 8, 9 at 1 and 5 minutes, respectively. The mother had three healthy babies delivered by normal vaginal route at home and one miscarriage. She was medically fit and had no medical problems during her current pregnancy and there is no consanguinity between parents. Routine antenatal ultrasound, done to the mother at 28 weeks of gestation, showed a distended bladder and bilateral hydronephrosis with preserved cortex of the kidney. These findings were consistent with partial bladder outlet obstruction.

On examination, she was a well looking baby with a birth weight of 2.3 kg. She was active with no dysmorphic features or external congenital anomalies. Her chest, cardiovascular, and central nervous system examination were unremarkable. Abdominal examination showed abdominal distention with the umbilicus shifted upwards. An 8x10 smooth, non tender abdominal mass was palpated. It was of pelvic origin and extended up to 4 cm above the umbilicus. The liver, spleen and kidney were not palpable. She had normal female genitalia with absent vaginal orifice, anus was patent.

The initial blood tests were normal, but the inflammatory markers got elevated during her hospital stay. Abdominal ultrasound (Figures 1 and 2) was done which showed the presence of a transverse vaginal septum with over distention of fluid filled uterus, bilateral hydronephrosis and hydroureter with preservation of kidneys size and paranchymal thickness, empty compressed urinary bladder.

The baby was admitted to the neonatal intensive care unit and was seen by the gynecologist and pediatric surgeon. A diagnosis of vaginal septum was made and she was planned to have a which was performed few days later. A transverse vaginal septum was found, a cruciate incision was done, and 200 ml of clear white fluid was drained and four stitches were applied. Fluid samples were taken for cytology and culture. The cytology result showed normal mature squamous cells in sheets, mixed with few inflammatory cells mature squamous in sheet and tissue fragments with few mixed inflammatory cells and red cells probably

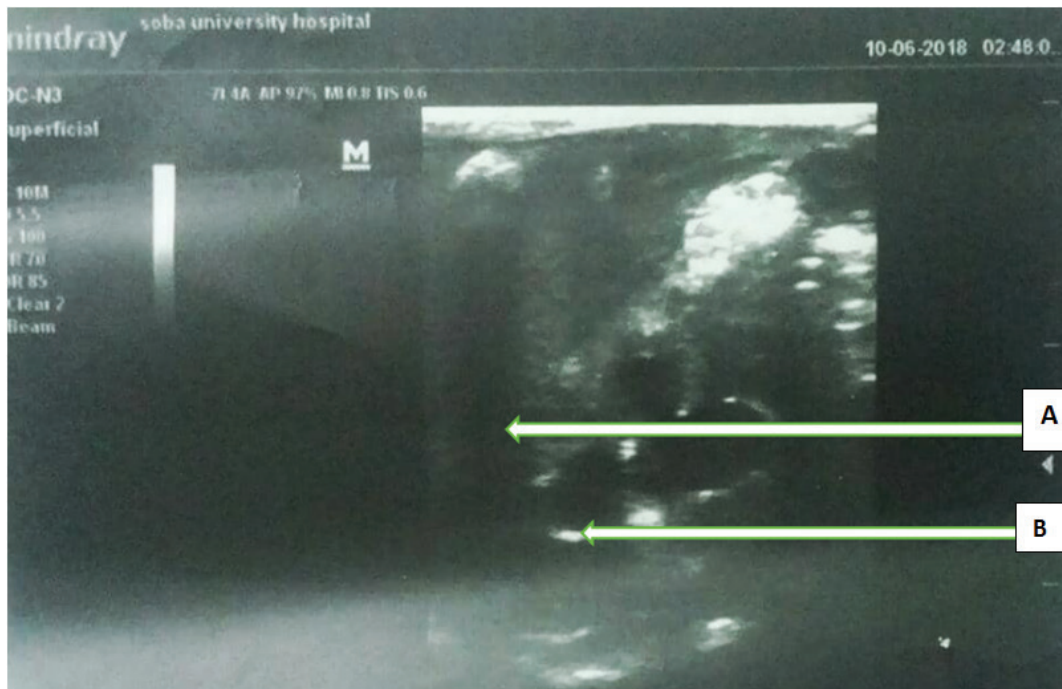
from vagina, the fluid culture revealed *Klebsiella pneumoniae*.

Two days post operatively, the baby developed minimal bloody vaginal secretions with fever which continued for 2 days and then subsided. Blood cultures grew *K. pneumoniae* and she received antibiotics according to blood culture sensitivities which were meropenem and amikacin injections. Postoperative ultrasound showed bilateral mild hydronephrosis and mild endometrial fluid collection with the disappearance of the lower abdominal mass.

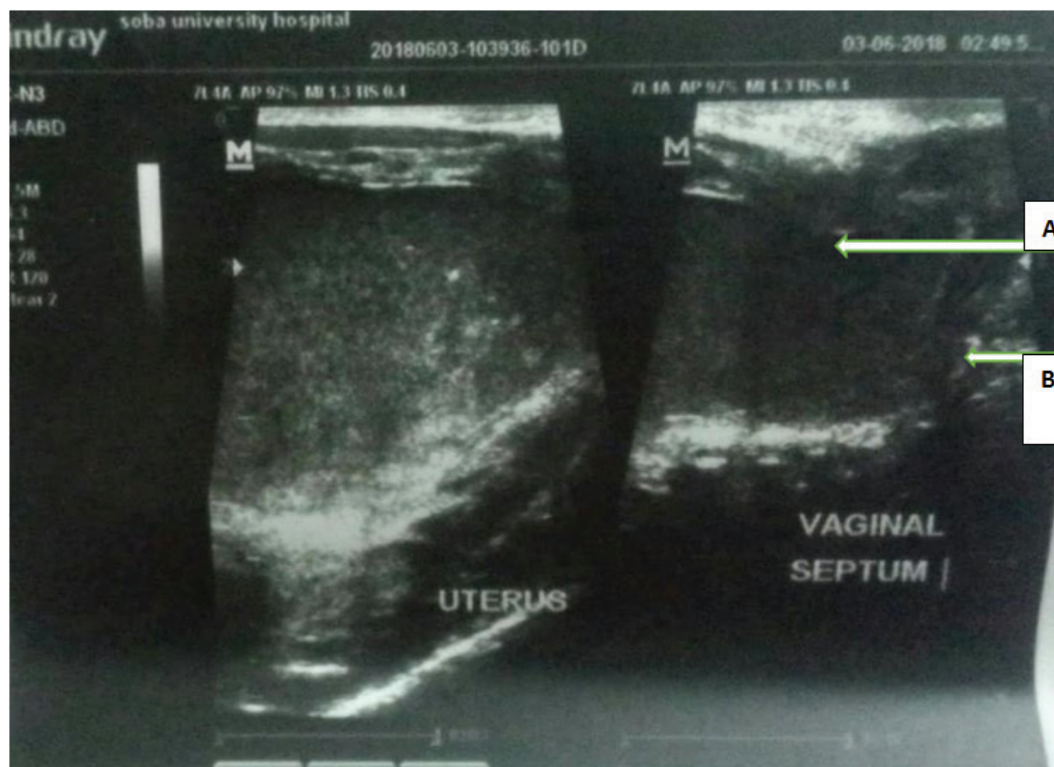
## DISCUSSION

Hydrocolpos is vaginal distension with fluid accumulation due to a combination of stimulated secretory glands and vaginal obstruction. The fluid accumulation can also be due to the presence of urogenital sinus with collection of urine [4]. Congenital obstructing lesions of vagina, hydrometrocolpos, and hematocolpos, present at a variable time during early childhood and adolescence to different medical and surgical specialties [5]. In a retrospective review done by Ameh et al. [2] on nine patients treated for vaginal obstruction before the age of 16 years, the most common presentation of the condition was intestinal or urinary obstruction. In the neonatal period, the most reported common presentations were in terms of frequency as follows: abdominal mass, neonatal sepsis, and respiratory distress [5]. The causes of vaginal obstruction were as follows in terms of frequency: six cases with low transverse vaginal septum, two cases with imperforate hymen, and one with high transverse vaginal septum [5]. Associated anomalies were present in five patients (three with persistent cloaca, one with Hirschsprung disease, and one with polydactyly) [2].

The approach to diagnose such cases relies on careful complete physical examination of the abdomen, perineum, and rectum preferably under general anesthesia [6]. The diagnosis is mainly confirmed with ultrasonography (US) or magnetic resonance imaging which helps define the location and thickness of the septum and distinguish a high septum from congenital absence of the cervix [7]. Antenatal diagnosis can be possible, and



**Figure 1.** Transabdominal ultrasound view demonstrating (A) the dilated uterus and (B) the vaginal septum.



**Figure 2.** A second view of the transabdominal ultrasound showing (A) the dilated uterus and the vaginal septum (B).

hydro(metro)colpos can be detected by US during gestation which may show a cystic mass arising posterior to the bladder. The amniotic fluid may be normal, increased, or decreased [8]. However, the antenatal ultrasound in our case only showed bilateral hydronephrosis and a distended bladder. In a study done in Germany by Mallmann et al. [9], the median diagnosis was made at 30+4 weeks of gestation. Several surgical treatment modalities have been developed to treat congenital transverse vaginal septa. Techniques include simple incision, surgical excision of the septum followed by approximation of the corresponding portions of the transversely cut edges of the upper and lower mucosal membranes of the septum [10].

## CONCLUSION

Hydrocolpos is a rare condition in the neonate and can have various presentations. A high index of suspicion is needed to reach the diagnosis and prenatal US can be a very important screening and diagnostic tool. This should be shortly followed by postnatal imaging to facilitate early intervention in order to prevent complications secondary to compression and obstruction of surrounding structures.

## Conflict of interest

There are no conflicts of interest.

## Funding

None.

## Ethical approval

Informed consent for participation and publication of medical details was obtained from the parents of this newborn. Confidentiality was ensured at all

the stages. Ethics clearance and approval of the study were granted from Soba University Hospital.

## REFERENCES

1. Reggiani G, Pizzol D, Trevisanuto D, Antunes M. Successful management of giant hydrocolpos in a limited-resource setting. *Oxf Med Case Rep.* 2018;2018(7):omy031.
2. Ameh EA, Mshelbwala PM, Ameh N. Congenital vaginal obstruction in neonates and infants: recognition and management. *J Pediatr Adolesc Gynecol.* 2011;24(2):74–8.
3. Stephany Heidi A, Ost Michael C. 15—urologic disorders. In: Zitelli Basil J, McIntire Sara C, Nowalk Andrew J, editors. *Zitelli and Davis' atlas of pediatric physical diagnosis.* 7th ed; 2018. pp 540–61. ISBN 978-0-323-39303-4, <http://dx.doi.org/10.1016/B978-0-323-39303-4.00015-3>. Available from: <https://www.clinicalkey.com/#!/content/3-s2.0-B9780323393034000153>
4. Nagaraj BR, Basavalingu D, Paramesh VM, Nagendra PDK. Radiological diagnosis of neonatal hydrometrocolpos—a case report. *J Clin Diagn Res.* 2016;10(3):TD18–9.
5. Nazir Z, Rizvi RM, Qureshi RN, Khan ZS, Khan Z. Congenital vaginal obstructions: varied presentation and outcomes. *Pediatr Surg Int.* 2006;22:749.
6. Panda SS, Bajpai M, Sharma N, Sing A, Jana M. Congenital hydrometrocolpos: a diagnostic dilemma. *J Prog Paediatr Urol.* 2013;16(2):62–4.
7. Goldstien DP. How to diagnose and repair congenital uterovaginal malformations. *OBG Manag.* 2008;20(3):52–63.
8. Saxena R, Divan G, Long AM, Arulambalam KJ, Nicolaides KH. Fetal hydrometrocolpos. *Ultrasound Obst Gynecol.* 1993;3:360–1.
9. Mallmann MR, Reutter H, Mack-Detlefsen B, Gottschalk I, Geipel A, Berg C, et al. Prenatal diagnosis of hydro(metro)colpos: a series of 20 cases. *Fetal Diagn Ther.* 2019;45(1):62–8.
10. Kaefer M. 149—management of abnormalities of the genitalia in girls. 11th ed. *Campbell-Walsh Urology.*